



# The five most effective ways to demonstrate spinal injuries

*Here are proven ways to present complex medical conditions to the jury in an understandable, yet compelling, manner.*

BY JEFF DAVIS

The two most important goals for any successful medical-legal illustration are to first take a complex condition or surgical procedure and make it clear and easy to understand; the second is to do it in a way that is extremely dramatic and persuasive. More jurors are impressed with experts who clearly communicate their expertise than experts who have “superior” credentials.

When it comes to spine injuries in personal injury cases, I have found that there are five common steps to visually tell your client’s story.

## MRIs

The first is the post accident/pre-operative injury as seen in the MRIs. Disc bulges, protrusions, herniations and nerve root impingements can be demonstrated clearly and dramatically by having the films converted into digital format, then “colorized.” Color-illustrated MRIs can clearly demonstrate the shape of a normal disc compared to where the disc has herniated or protruded into the thecal sac and spinal cord or nerve root.

Easy-to-understand labels and an orientation illustration are key. It is important to orientate the viewer as to where the cervical or lumbar spine in the MRI is located in the first place. You can have an

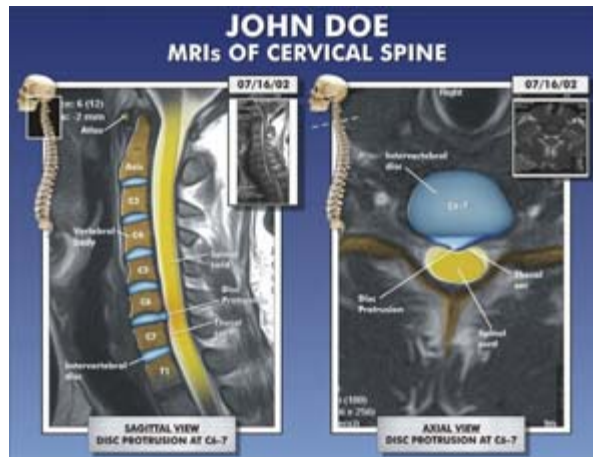


Image 1

extremely detailed colorized MRI but the average person won’t quite understand where what you are showing them is in someone’s body. It is important to be sure that it is clear not only where the image is but what viewing plane it is. For example, will they understand the difference between sagittal, axial or coronal views when looking at your film? By looking at a color illustrated and labeled MRI, someone with even an 8th grade education should be able to locate the different levels of vertebral bodies and intervertebral discs.

They can see where the thecal sac and cord are located and where the disc is now abnormal.

Before sending your client’s MRIs to the exhibit company, it is always a good idea to have duplicates made, just in case

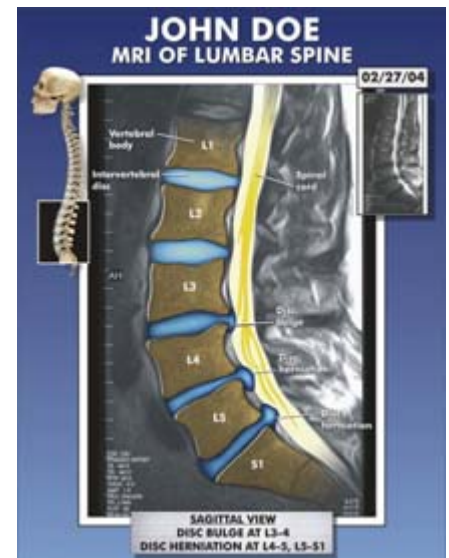

Image 2

the originals are lost. Another important thing to provide the medical illustrator along with your films are the radiology reports that go with the different dates of the films. By using these records, the illustrator can use the exact same wording as was used by the radiologist. For example, if the radiologist uses the wording “herniation at L4-5”, it is labeled on your exhibit as “herniation at L4-5” and not “bulge” or “protrusion” at L4-5. (See Images 1 and 2.)

## Pain Management Injections

Another effective step in telling the story is showing a summary of pain management injections over a period of time.

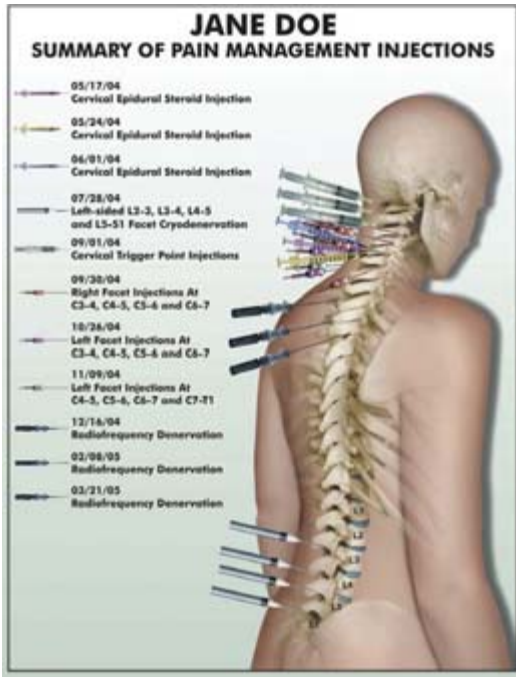

Image 3

Often times this opportunity to make a compelling point is overlooked. On one single exhibit you can visually demonstrate every date your client has had an injection, the location of each injection and even the size and shape of each needle and syringe or otherwise entering the spine. By listing the injection dates in chronological order on the side of the layout in addition to the illustration, the exhibit also serves as a visual timeline. To have a multiple injections exhibit made, the attorney or paralegal will need to provide the medical illustrator with either each report from an injection date or a written summary listing the injection dates, types of injections given and the locations. When people see a multi-

ple injection exhibit they often literally moan and groan out loud! (See Image 3.)

**Surgical Illustrations**

In cases where a surgical procedure has been (or will be) performed due to your client’s injury, surgical illustrations are a useful way of visually explaining the complex steps of the procedure. For example, medical illustrations of a common procedure such as an anterior cervical discectomy and fusion tell the next stage of your client’s story, the subsequent procedure or in some cases multiple procedures that have been performed as a result of the injury. These surgical illustrations can be very case specific or more generic.

Case-specific illustrations take the information directly from your client’s operative reports and graphically explain the steps of your client’s exact surgery step by step. Generalized exhibits with no name or specific date allow you to reuse your exhibit again in future cases involving the same type of operation or condition.

In some cases, you may not be sure if the procedure is worth creating an il-

lustration for. Other times, you may have several operative reports and are not sure which surgical procedures would be the most dramatic to have depicted. The good news is that just about every medical-legal exhibit company will provide you with a free, detailed written proposal. The proposal should list each step of the operation to be depicted and what the fee would be to create your exhibit. Once everything is agreed upon between the attorney and the exhibit company, a first draft can generally be expected within around two weeks for custom illustrations and just a few days for stock illustrations. (See Image 4 on previous page.)

**Post-Operative X-rays**

Usually, the final step is to show the post-operative condition. X-rays are the best type of film to use for showing the post-op hardware. In regular X-rays, the hardware is seen as plain white and is not fully appreciated by the laymen. With the use of color illustrated X-rays, it is easy to see where bone is bone and where the plates, rods and screws are just that. The use of medical illustration allows you to show the screws as shiny metallic screws as they actually are. Often times, many of my clients did not realize the full extent of an injury until it was color illustrated. Similar to the pre-op MRIs that show the herniation, spondylolisthesis, compression fractures or otherwise, it is always a good idea to include the radiology reports with the post-op X-rays as well. This way the terminology in your exhibit will match the terminology used to describe the types of internal fixation mentioned in the reports. (See Image 5 on previous page.)

**3D Animation**

A few years ago, I would have called this article the four most effective ways to demonstrate spine injuries instead of the five most. Many of the artists that excel in this next area may have actually even been born after the day you passed your bar exam! I would be leaving out an ex-

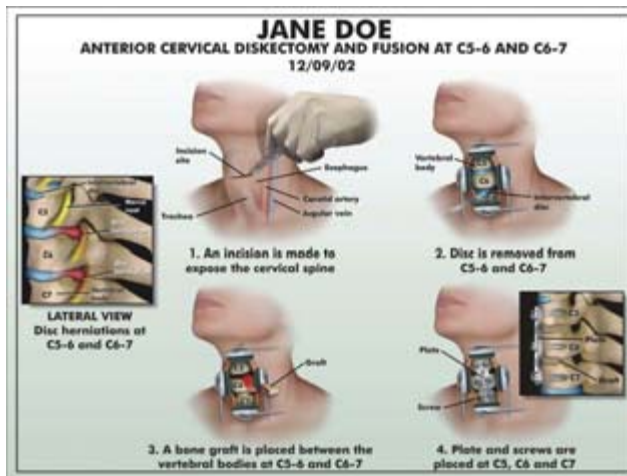


Image 4

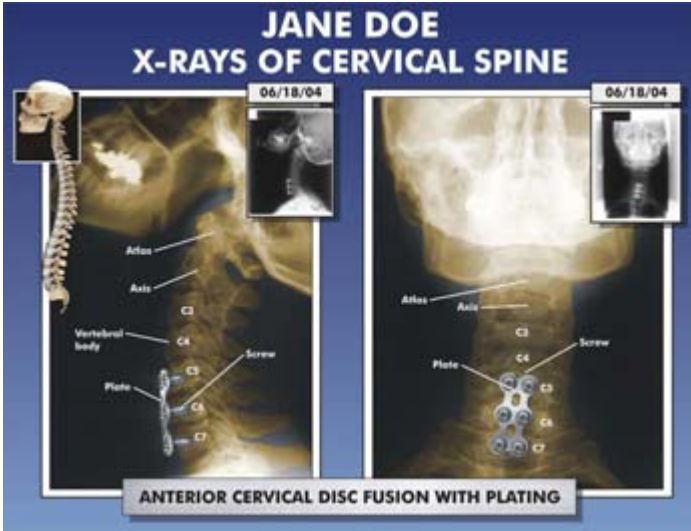


Image 6

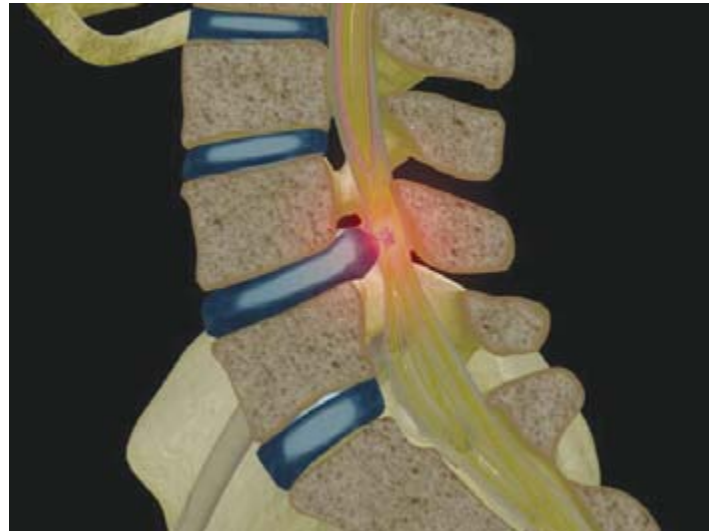

Image 7

tremely impressive technique for demonstrating a spine injury if I didn't mention the use of 3D animation.

Although computer animation is the highest in price of the five methods discussed in this article, with today's emerging technology it is being used more and more frequently. Of all the methods suggested in this article, 3D computer animation is the only method that allows you to three-dimensionally rotate and zoom in and out of the spine with motion-picture-like quality. In addition to

demonstrating the injury, this method also allows you to animate how the injury occurred in the first place. (See Image 6.)

Try to get the wheels in motion as early as possible so that you give yourself enough time to send a draft to your medical expert. I strongly suggest that you let your expert see the illustrations, color illustrated films or animations ahead of time so that any adjustments they want made or anything they may see a bit differently are suggested in advance and not in front of a jury or mediator!



Davis

*Jeff Davis is the founder, president and CEO of Legal Art Works (www.legalartworks.com). Legal Art Works' exhibits and 3D animations are used by trial attorneys across the United States to help generate larger settlements and verdicts. Jeff Davis can be reached at (904) 356-0111 or by e-mail at jeff@legalartworks.com.*

